

Expression of *Survivin* in the Formalin-Fixed, Paraffin-embedded Specimens of Human Osteosarcoma May Be Used as a Diagnostic Marker

Esmail Babaei¹, Bashdar Mahmud Hussen², Maryam Abedi¹ and Hewa Jalal Azeez¹

¹ Department of Animal Biology, School of Natural Sciences, University of Tabriz, Tabriz-Iran

² College of Pharmacy, Hawler Medical University, Erbil, Iraq

ARTICLE INFO

Article history:

Received 18 December 2019

Accepted 19 January 2020

Available online 31 January 2020

Keywords:

Tumor marker

Real-time PCR

FFPE blocks

Immunohistochemistry

Corresponding author:

✉ E. Babaei

babaei@tabrizu.ac.ir

p-ISSN 2423-4257

e-ISSN 2588-2589

ABSTRACT

Osteosarcoma is the most frequent malignant bone tumor with a peak incidence in the second and third decades of life. Diagnosis of patients with osteosarcoma is limited to clinico-pathological parameters whereas molecular markers of tumor initiation and promotion have not yet been identified. We aimed to study the expression of the anti-apoptotic survivin gene in osteosarcoma specimens. A total of 35 formalin-fixed, paraffin-embedded (FFPE) specimens including 25 tumoral and 20 non-tumoral paired-margins were collected. The expression of survivin was evaluated by employing real-time PCR and immunohistochemistry. Our data showed that survivin is differently expressed in osteosarcoma samples rather than non-tumoral margins. Real-time PCR showed that survivin is up-regulated in osteosarcoma specimens compared to margins ($p < 0.01$). Furthermore, IHC confirmed that the survivin protein is significantly found in malignant parts of paraffin blocks. Our data show that survivin expression is modulated in osteosarcoma and may be considered as a diagnostic marker for further studies.

© 2015 UMZ. All rights reserved.

Please cite this paper as: Babaei E, Hussen BM, Abedi M, Azeez HJ. 2020. Expression of *survivin* in the formalin-fixed, paraffin-embedded specimens of human osteosarcoma may be used as a diagnostic marker. *J Genet Resour* 6(1): 49-53. doi: 10.22080/jgr.2020.18366.1175

Introduction

Osteosarcoma is the most frequent highly malignant bone tumor and the third most common malignancy in children and adolescents. This malignancy derives from mesenchymal cells of bone tissues and exhibits a peak incidence during the second and third decades of life (Moore *et al.*, 2014). Diagnosis and prognosis of osteosarcoma, as well as decision for therapeutic strategies, require a multidisciplinary approach including a family physician, orthopedic oncologist, radiologist, and pathologist. Furthermore, they sometimes have a diversity of opinions in their decisions (Saraf *et al.*, 2018). Therefore, the most important problem for managing osteosarcoma is the lack of suitable clinicopathological criteria for classifying the tumors. Therefore, the determination of the type and intensity of the treatment is quite hard (Varshney *et al.*, 2016).

In recent years, numerous molecular studies of osteosarcoma have been undertaken that have yielded varied and often conflicting results. So far, these studies have been of limited value in diagnosis, prognosis and understanding of the molecular events driving tumorigenesis in osteosarcoma (Varshney *et al.*, 2016; Zamborsky *et al.*, 2019). Additionally, the overall rarity of these tumors limits broad range studies. Nonetheless, using formalin-fixed, paraffin-embedded (FFPE) tissue sources could be useful in the extension of molecular evaluations to yield important information suggesting potential marker in initiation and progression of osteosarcoma (Otoukesh *et al.*, 2018).

Tumor growth depends on two main cellular pathways including proliferation and cell death or apoptosis (Cao *et al.*, 2018). Apoptosis is a form of cell death characterized by morphological, biological and genetic features. Suppression of apoptosis may lead to

uncontrolled cellular proliferation and ultimately tumorigenesis. Several studies have reported significant correlations between apoptosis and tumor initiation in the lung (Liu *et al.*, 2017), breast (Zambrano *et al.*, 2016) and thyroid tissues (Kyani *et al.*, 2014).

The regulation of apoptosis may play a central role in the development of neoplastic cellular proliferative processes and may exert a strong influence on tumor progression. Survivin, an inhibitor of apoptosis protein (IAP), is expressed both during normal fetal development and in a broad spectrum of human cancers (Ambrosini *et al.*, 1997). Since there is a correlation between the expression of survivin and unfavorable outcome of cancer, it may be used as a specific molecular marker for diagnosis, prognosis, and classification of malignant tumors.

As part of our continuous effort (Babaei *et al.*, 2006), we quantitatively investigated the expression of the survivin gene as a potential tumor marker for the diagnosis of osteosarcoma (Jaiswal *et al.*, 2015). Our data revealed that the upregulation of survivin is limited to high-grade osteosarcoma rather than non-tumoral specimens. This finding indicates that the evaluation of survivin expression might be a useful molecular marker for the diagnosis of osteosarcoma.

Materials and Methods

Sample collection

FFPE tissue specimens were obtained from 25 patients with subtypes of high-grade osteosarcoma. About 20 samples of paired-non tumoral margins were also collected as control. These samples were pathologically evaluated and selected by a pathologist as described before (Babaei *et al.*, 2006). These blocks accumulated from the tumor bank of the cancer research institute at Imam Hospital of Tehran University of medical sciences. All FFPE blocks were cleaned and processed for sections with a thickness of 10 μm .

RNA extraction

RNA was extracted from FFPE sections by *FFPE high pure RNA kit* (Ambion Co., USA) as instructed by the manufacturer. Briefly, three to five Ten-micrometer tissue sections were obtained and assembled. Carryover from block

to block is prevented by clearing the microtome blade with xylene and ethanol 100% (Kraft *et al.*, 1997). Immediately, the sections were processed for RNA extraction. Deparaffinization was done by xylene solution in two steps for the elimination of paraffin. After deparaffinization, plates were followed by proteinase K digestion for five hours. Then, DNA contamination was eliminated by DNase I treatment (Sima-Aldrich, USA). The purity and integrity of extracted RNAs were determined by Nanodrop (Thermo Fisher, USA).

Real-time PCR

CycleScript™ RT PreMix reagent (Takara Bio, Japan) was used for cDNA synthesis according to manufactures instructions. Quantitative PCR was done using 2 μl SYBR Green Master Mix (Takara Bio, Japan), 250 nM of appropriate primers and 200 ng of the generated cDNAs. The thermal cycler conditions were as follow 95 °C for 300 sec. as initial denaturation, followed by 40 cycles at 95 °C for 5 sec., annealing at 58 °C for 30 sec., extension at 72 °C for 30 sec., and a final extension at 72 °C for 300 sec. All reactions were done in triplicate (Illumina eco, USA). The comparative threshold cycle (Ct) method was employed to study the relative quantifications (Jannat Alipoor *et al.*, 2017). ΔCt (Ct (relative Gene) - Ct (β2m as an internal control)) and $\Delta\Delta\text{Ct} = \Delta\text{Ct}$ (Treated) - ΔCt (Untreated) formulas were used to normalize Ct values for each gene and also, to determine the relative expression levels, respectively. The values were used to plot the expression of genes using the general formula $2^{-\Delta\Delta\text{Ct}}$. The sequences of primers used in PCR were designed in Gene Runner V.3.6 software and synthesized by Metabion Co. (Germany). The best sequences were chosen as table 1.

Immunohistochemistry

To further confirm the expression of survivin in osteosarcoma FFPE specimens, immunohistochemistry was done by specific antibodies. Polyclonal rabbit serum antibody (Ambion Co., USA) was used as the manufacturer's instruction. Five-micrometer tissue sections were collected on glass slides, dried in the oven, deparaffinized in xylene twice, and rehydrated in graded alcohol baths each one

5 minutes (min.), and finally rinsed in washing buffer (Phosphate Buffer Salin; 0.01M, PBS pH 7.2) for 5 min. twice. Quenching of endogenous peroxidase was done in 3% H₂O₂ diluted by methanol for 15 min. Also, antigen retrieval was performed by incubation in Citrate Buffer; 9 mM pH 6.0 in the bathroom for 12 min.

Table 1. The sequences of primers.

Gene	Primer sequence (5'→3')	PS (bp)*
β2m	F: 5'-CTACTCTCTCTTCTGGCCTG	191
	R: 5'-CTATCCAGCGTACTCCAAG	
Survivin	F: 5'-GACGACCCCATAGAGGAACATA	103
	R: 5'-CCAGTTTCAAAAATTCACCAAG	

*PS (bp)= Product size (base pair)

After washing for 10 min, slides were incubated in the primary antibody at 1/500 dilution for 24h at 4° C. Control slides incubated with washing buffer without primary antibody. Subsequently, the slides were incubated with a goat secondary Biotinylated anti-rabbit IgG (Ambion Co., USA) at a dilution of 1/500 for 12h at 4° C. Finally, staining was visualized using 2-4 diaminobenzidine/H₂O₂ and rehydrated in graded alcohol and xylene.

Data analysis

The results were analyzed by One-way ANOVA test in SPSS ver 18 to compare the differential expression between tumor and non-tumor samples. The values of *p* < 0.05 accepted as statically significant. All experiments were done at least three times.

Results

Expression of Survivin in osteosarcoma

Real-time PCR was employed to detect the expression levels of mRNAs in FFPE specimens. Because of the nature of FFPE blocks, the extracted RNAs are degraded and could only be used for PCR products lower than 200 nucleotides long. Figure 1 illustrated the expression of the survivin in tumor samples. PCR products show that survivin and β2m could be detected in FFPE sections.

To quantify the expression of survivin in osteosarcoma specimens as well as non-tumoral margins, real-time PCR was done. Data analysis (Fig. 2) showed that survivin is significantly up-regulated in osteosarcoma specimens rather than non-tumoral samples (*p*<0.01).

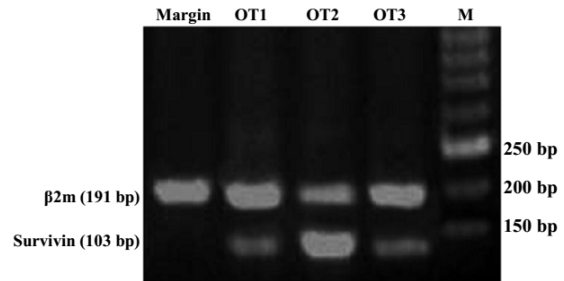


Fig. 1. RT-PCR for β2m and surviving: M) marker; Margin) samples collected from non-cancerous parts of the tumor; OT1-OT3) osteosarcoma tumors.

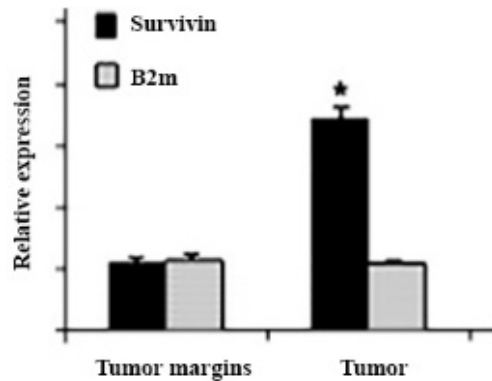


Fig. 2. Real-time PCR for RNA s extracted from FFPE samples. * shows the significant differential expression of the survivin in osteosarcoma compared to the margins (*p*≤ 0.01).

To further confirm survivin expression in tumoral samples, we employed immunohistochemistry (IHC) by using specific antibodies for survivin and β2m. IHC is a specific immunoassay that not only detects proteins but also, shows their subcellular localization. As fig. 3 shows, survivin protein is differentially expressed in cancerous parts of FFPE sections. However, it could not be detected in tumor margins that were pathologically non-tumoral.

Discussion

A direct correlation of the nature of malignancy with the expression of the survivin gene in human osteosarcoma was the assumption of this study. Until now, all bone tumors are classified only according to conventional pathologic criteria and the only generally approved prognostic factors for osteosarcoma are tumor size and response to chemotherapy (Lau *et al.*, 2009).

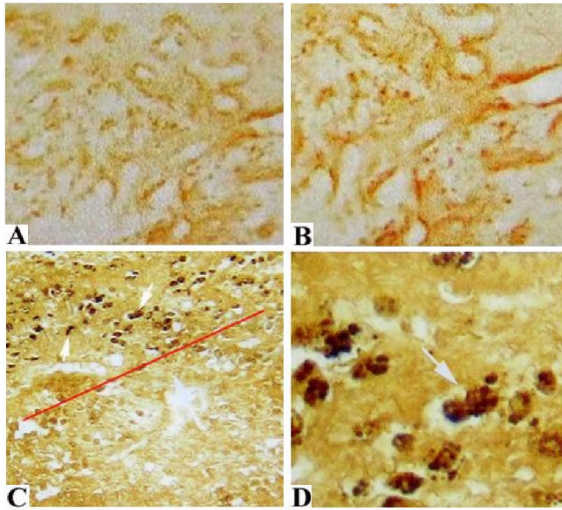


Fig. 3. Immunohistochemical analysis of survivin protein in FFPE blocks: A) Negative control without secondary antibody ($\times 1000$); B) Negative control without primary antibody ($\times 1000$); C) survivin visualization in cancerous and noncancerous part of a tumor ($\times 400$); D) Survivin protein detected in tumor cells ($\times 1000$); Line shows the boundary between tumor and margin. Arrows show the location of survivin protein inside cells.

In recent years, many efforts have been done to introduce a (some) specific molecular marker to clarify the heterogeneous nature of osteogenic sarcoma and predict the potential outcome of the disease. The introduction of an effective molecular marker empowered us to develop new strategies in the treatment of osteosarcoma, e.g., a preoperative stratification of neoadjuvant chemotherapy (Otokesh *et al.*, 2018). The evaluation of the expression of genes with biomarker potential could facilitate tumor management in classification and also, in defining the appropriate therapy. To date, this stratification is done postoperatively by using histological and pathological evaluation of tumors because of the lack of reliable markers. Based on our previous preliminary reports, we aimed to further study the biomarker potential of the anti-apoptotic survivin gene in FFPE blocks of osteosarcoma samples.

Our data showed that 22 of 25 biopsy patients have the expression of survivin (88 %). These patients haven't undergone any therapy procedures and have been referred to as the first of their disease. This is in concordance with

previous reports that survivin is overexpressed in osteosarcoma tumor tissues and related cell lines (Zou *et al.*, 2010). Three biopsy samples were negative for survivin expression that could be of some patches of necrosis, presence of ossification and low N/C (nuclear/cytoplasm) seen in slides. High N/C, high mitotic index and hypercellularity represent the proliferative characteristics of tumors and illustrate their higher malignancy nature.

It has previously shown that the expression of survivin is a poor prognosis for cancer and is significantly correlated with adverse outcome in malignancies (Guindalini *et al.*, 2013).

To further confirm the presence of survivin in osteosarcoma samples, IHC was employed by using specific antibodies. Microscopic figures taken from IHC slides showed that survivin is predominantly expressed in heterogenic cancerous parts rather than non-tumoral margins. This finding confirmed the previous report by Nie and his colleagues who detected survivin expression in osteosarcoma by IHC and concluded that this gene could be a therapeutic target (Nie *et al.*, 2005).

In our study, there was a limitation in the collection of appropriate specimens having FFPE blocks from tumor and non-tumoral margins. Therefore, only 25 samples were finally obtained.

The results of the current study indicate that the presence of survivin could be an important tumoral marker for the prediction of being cancer cells and the survival of patients with high-grade osteosarcoma. Therefore, survivin analysis could facilitate the diagnosis of the osteosarcoma and preoperative stratification for appropriate decision of treatment towards the progress of the tumor.

Conflicts of interest

The authors have no conflict of interest to declare.

References

- Moore DD, Luu HH. 2014. Osteosarcoma. *Cancer Treat Res* 162: 65-92.
- Saraf AJ, Fenger JM, Roberts RD. 2018. Osteosarcoma: accelerating progress makes for a hopeful future. *Front Oncol* 8(4): 1-7.

- Varshney J, Scott MC, Largaespada DA, Subramanian S. 2016. Understanding the osteosarcoma pathobiology: a comparative oncology approach. *Vet Sci* 18: 3(1). doi: 10.3390/vetsci3010003.
- Zamborsky R, Kokavec M, Harsanyi S, Danisovic L. 2019. Identification of prognostic and predictive osteosarcoma biomarkers. *Med Sci (Basel)* 11: 7(2). doi: 10.3390/medsci7020028.
- Otoukesh B, Boddouhi B, Moghtadaei M, Kaghazian P, Kaghazian M. 2018. Novel molecular insights and new therapeutic strategies in osteosarcoma. *Cancer Cell Int* 18: 158. doi: 10.1186/s12935-018-0654-4
- Zou J, Gan M, Mao N, Zhu X, Shi Q, Yang H. 2010. Sensitization of osteosarcoma cell line SaOS-2 to chemotherapy by downregulating survivin. *Arch Med Res*. 41(3): 162-169.
- Cao K, Tait SWG. 2018. Apoptosis and cancer: force awakens, phantom menace, or both? *Int Rev Cell Mol Biol* 337: 135-152.
- Liu G, Pei F, Yang F, Li L, Amin AD, Liu S, Buchan JR, Cho WC. 2017. Role of autophagy and apoptosis in non-small-cell lung cancer. *Int J Mol Sci* 10: 18(2). doi: 10.3390/ijms18020367.
- Zambrano J, Yeh ES. 2016. Autophagy and apoptotic crosstalk: mechanism of therapeutic resistance in HER2-positive breast cancer. *Breast Cancer (Auckl)* 13(10): 13-23.
- Kyani K, Babaei E, Hosseinpour Feizi MA, Vandghanooni S, Montazeri V, Halimi M. 2014. Detection of survivin 2 α gene expression in thyroid nodules. *J Cancer Res Ther* 10(2): 312-20.
- Ambrosini G, Adida C, Altieri DC. 1997. A novel anti-apoptosis gene, survivin, expressed in cancer and lymphoma. *Nat Med* 3(8): 917-21.
- Jaiswal PK, Goel A, Mittal RD. 2015. Survivin: a molecular biomarker in cancer. *Indian J Med Res* 141(4): 389-97.
- Babaei E, Mowla SJ, Torbaghan S, Emadi Bayegi M. 2006. Detection of Survivin gene expression in formalin-fixed paraffin-embedded tissues of human osteosarcoma: its potential usefulness in diagnosis and prognosis of bone tumors. *Iran Biomed J* 10 (1): 39-45.
- Jannat Alipoor F, Asadi M, Torkzadeh-Mahani M. (2017). LncRNA Miat Promotes Proliferation of Cervical Cancer Cells and Acts as an Anti-apoptotic Factor, *J Genet Resour* 3(2): 80-86.
- Lau CC. 2009. Molecular classification of osteosarcoma. *Cancer Treat Res* 152: 459-65
- Guindalini R, Mathias Machado MC, Garicochea B. 2013. Monitoring survivin expression in cancer: implications for prognosis and therapy. *Mol Diagn Ther* 17 (6): 331-42.
- Nie T, Daim, Zong S. 2005. Expression of survivin gene and its relationship with clinical multidrug resistance in osteosarcoma. *Chin Ger J Clin Oncol* 4: 164-166.