

Study of Blood Parasites of the Three Snake Species in Iran: *Natrix natrix*, *Natrix tessellata* and *Zamenis longissimus* (Colubridae)

Seyedeh Sara Sajjadi and Hossein Javanbakht*

Department of Biology, Faculty of Science, University of Guilan, Rasht, Iran

*Corresponding author: h.javanbakht@gmail.com

Received: 13 July 2016

Accepted: 08 January 2017

Abstract

Infections with blood parasites are common phenomenon in reptiles from all over the world. Apicomplexan are the majority of blood parasites that frequently occur with high levels of parasitaemia in the snakes. The aim of this study was to determine the presence of blood parasites in some snakes Guilan province in the North of Iran. A total of 51 specimens of three snake species were captured including 18 specimens of *Natrix natrix*, 30 of *Natrix tessellata* and three from *Zamenis longissimus*. Blood sampling was carried out from the caudal vein by insulin syringe. The blood smears were stained with Giemsa solution and examined by light microscopy for haemoparasites. We found one species of *Hepatozoon sp.* as well as two intra-erythrocytic structures that we referred them to *Rickettsia* and *Serpentoplasma* in the snakes. The *Serpentoplasma* with small amoeboid shape only detected in *N. tessellate*. But the *Rickettsia* which is bigger in size and formed roughly spherical inclusions detected in both *Natrix species*. This finding of haemoparasites represents for the first time in these snakes.

Key words: Apicomplexa; *Hepatozoon*; Blood parasite; Snakes

Introduction

Apicomplexa are a large unicellular clade belongs to protist, composed taxon whose members are entirely the obligate intracellular parasites (Morrison, 2009). It is said that Apicomplexa with estimates of only 0.1% of the known their species is the poorly described species regarding its biodiversity (Morrison, 2009). Haemogregarines belong to the suborder Adeleorina, mainly from the *Haemogregarina*, *Hepatozoon* and *Karyolysus*, the most group of Apicomplexan haemoparasites, which widely distributed in reptiles (Telford, 2009). Parasites of the genus *Haemogregarina* are commonly reported in various species of terrapins (Telford, 2009), while the *Hepatozoon* (Miller, 1908) and *Karyolysus* (Labbé, 1894) are the most widespread Apicomplexan parasite infecting different species of snakes and lizards (Cook *et al.*, 2016).

Haemogregarine parasites generally are heteroxenous including invertebrates and vertebrates hosts. Merogony and the formation of gametocytes (commonly in circulatory

system) take place in vertebrate hosts and gamogony and sporogony occur in the gut of an invertebrate host. Mosquitoes, ticks, mites and leeches have been reported as vectors (Telford, 2009). However, many authors have described the haemogregarines only basis of morphology of gamont in erythrocytes and their life cycles of many species are not elucidated. Smith (1996) placed the most of the snake haemogregarines in the genus *Hepatozoon*. The life cycle of *Hepatozoon spp.* in snakes that feed of frogs is heteroxenous. Sporogony occur in a blood feeding arthropod as vector, then the arthropod ingested by frog as first intermediate host and consequently cystozoites produce in the frogs and merogony and gametogony in the snakes as second invertebrate host (Smith, 1996).

Although many species of haemogregarines reported from the Palearctic region but data on blood Apicomplexan parasites of Iranian reptiles are scarce and only limited to turtles (Javanbakht *et al.*, 2015a). One of the first species of reptilian hemoapicomplexan in Iran was *Haemogregarina stepanovi* (Danilewsky, 1885) in *Emys orbicularis* and *Mauremys*

caspica (Dvorakova, 2013, Nasiri *et al.*, 2014). Javanbakht *et al.* (2015b) described haemosporidian Apicomplexa in the Palaearctic tortoises including Iran. The distribution and abundance of *Hemolivia mauritanica* in tortoises of Iran were investigated by Javanbakht *et al.* (2015a). Recently, Rajabi *et al.* (2017) described *Hemogregarina magna* from the marsh frog (*Pelophylax ridibundus*) in the north of Iran. However, there is no data on haemoparasites of snakes in Iran.

Two species of water snake reported in Iran; the dice snake, *Natrix tessellata* (Laurenti, 1768) and the grass snake, *Natrix natrix* (Linnaeus, 1758). The first species is semi-aquatic snake, hunts mostly on fish (Mebert, 2011) and the second one semi-aquatic snake and forages predominantly on anurans (Latifi, 2000; Szczerbak, 2003). They are found in large numbers in the Northern provinces, including Guilan, Golestan and Mazandaran (Latifi, 2000). The aesculapian snake (*Zamenis longissimus*) a member of the family Colubridae, mostly distributed in Europe. It is reported in fragmented areas in north and northwest of Iran (Latifi, 2000). The aim of this study is the morphological description of blood cells of some snakes of North of Iran in order to detect potential infections by haemoparasites.

Material and Methods

Specimens were capture during spring and summer 2016-2017 from three snake species. Three specimens of *Zamenis longissimus* and 48 specimen of *Natrix natrix* and *N. tessellata* were sampled from Guilan Province in the North of Iran. Blood smears were collected from the ventral caudal vein using an insulin syringe.

Thin blood smears air-dried and were fixed in absolute methanol and were stained using Giemsa solution for 15–20 minutes (Javanbakht *et al.*, 2015a). The parasites were investigated by the light microscope under 100X oil immersion. Intensity of infection (parasitemia) was estimated for 10^4 red blood cells (RBCs). All measurements and photographs were done using TSVIEW software version 6.2.4.5 (Rajabi *et al.*, 2017). The morphological characteristics of the parasites were examined according to Telford

(2009). All measurements were given in μm ; additionally, LW value (length \times width) and the shape index as L/W ratio were calculated. Computer program SPSS 16 was applied to calculation of parasites measurements (Mean \pm SD).

Results

A total of fifty-one blood smears from snakes, 18 specimens of *N. natrix*, 30 specimens of *N. tessellata* and three specimens of *Z. longissimus* were examined. The blood parasites were found inside the red blood cells in 11 specimens including two *Z. longissimus*, three *N. natrix* and five *N. tessellata* (Figs. 1, 2, 3).

Basis on the morphological characters of gametocytes, *Hepatozoon* sp. was observed in the RBC of two specimens of *Z. longissimus* (Fig. 1). The Measures were; LW $13.90\pm 0.58 \times 5.56\pm 0.33$ ($12.85\text{--}15.10 \times 4.86\text{--}6.02 \mu\text{m}$), LW $62.45\text{--}90.2 \mu\text{m}$, L/W 2.64–2.50 (n=25). The mean intensity of *Hepatozoon* sp. in infected snakes was 1.8 per 10^4 RBCs. The examination of blood cells in *Natrix* species showed the presence of rickettsial infection (Fig. 2).

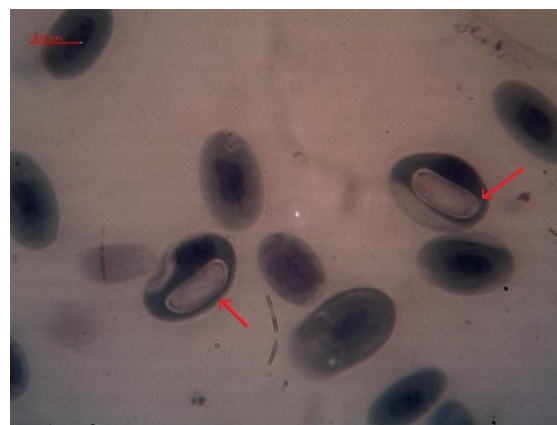

Fig. 1. *Hepatozoon* sp. in blood cells of *Zamenis longissimus*

These parasites were roughly spherical inclusion bordered by a darker stained margin associated with a vacuole (occurring in snakes). They were usually round to oval in shape, the small size ($3\text{--}9 \times 3\text{--}7.2 \mu\text{m}$) and observed in three specimens of *N. natrix* as well as three specimens of *N. tessellata* (Fig. 2). The prevalence of rickettsial organism in *N.*

natrix and *N. tessellata* were 16.66% and 10%, respectively. Of 30 specimens of *N. tessellata*, two specimens infected with intraerythrocytic vacuoles mainly amoeboid shape that did not show evident of nucleus or other structures (Fig. 3). Some of them had a dark-purple ring around the vacuole. We identified them as *Serpentoplasma*. None of *N. natrix* infected with *Serpentoplasma*.

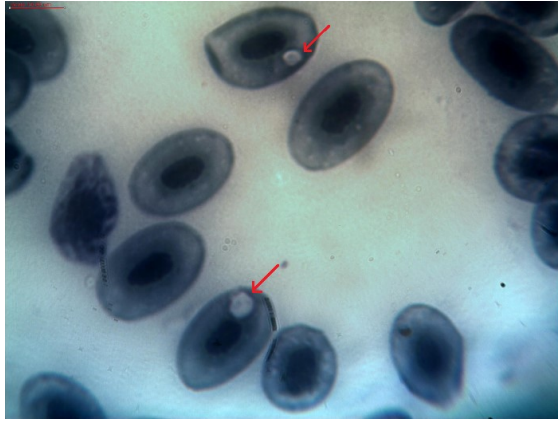


Fig. 2. Two intraerythrocytic *Rickettsia* of the *Natrix natrix*

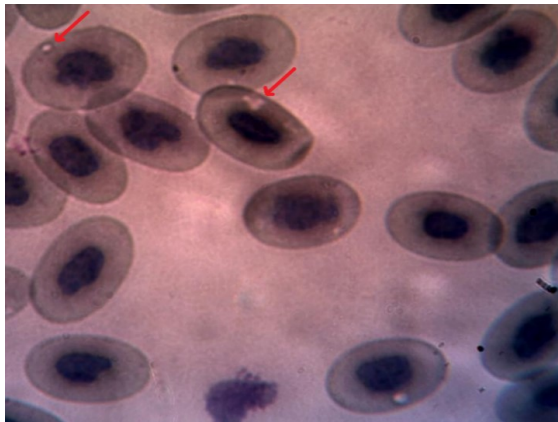


Fig. 3. *Serpentoplasma* in blood cells of *Natrix tessellata*

Discussion

Parasites of the haemogregarine complex are classified with their sporogonic stages in the invertebrate hosts (Telford, 2009). Their intraerythrocytic stages in the reptiles are known with an elongate to bent cell and its prominent dark nucleus. *Hepatozoon* sp. infection frequently has been reported from ophidian hosts (Levine, 1988). Transmission of

Hepatozoon in ophidian occurs when first intermediate hosts namely frogs or lizards (infected by hematophagous mosquito as a definitive host), eaten by the snakes (Sloboda *et al.*, 2007). In addition, other vertebrates like rodents might serve as paratenic hosts (Sloboda *et al.*, 2008). However, the present study provides the first report of *Hepatozoon* species in the snakes of Iran. Although it is not clear which hematophagous arthropods act as final hosts of *Hepatozoon* in *Z. longissimus*.

In the present study 2 out of 3 specimens of *Z. longissimus* (33.33%) were infected by *Hepatozoon* sp. Ursula *et al.* (2014) showed that the prevalence of *Hepatozoon* in the ball python, *Python regius* (Shaw, 1802) and the emerald tree boa, *Corallus caninus* (Linnaeus, 1758) is approximately 75%. The size of the parasites in current study was not completely similar to those of *Python regius* ($13.5 \pm 2.6 \times 3.4 \pm 0.7$) and *Corallus caninus* ($13.8 \pm 1.8 \times 3.9 \pm 1$) reported by Ursula *et al.* (2014). In addition, the morphological size (LW and L/W) of *Hepatozoon* in our study was not completely within the size range of *Hepatozoon* reported by Sloboda *et al.* (2007). However, Sloboda *et al.* (2007) stated the morphology of gamonts in *Hepatozoon* in the same species may be due difference induced by hosts. Meanwhile, in associated with environmental factors and microhabitats, some differences in prevalence and intensity of haemoparasites between or within host species can be occur (Davis *et al.*, 2012).

The *Hepatozoon* gamonts have been described from snake's species in different localities (Davis *et al.*, 2012; Ursula *et al.*, 2014). Nevertheless, the morphological characters of *Hepatozoon* sp. in our study was not completely identical to the previous studies. Identification of these protists to species level is impossible only by the morphology of gamonts as well as identification of hemogregarines species based only on morphological characteristics and molecular data is essential for identification of these Apicomplexan parasites. This study is the first report of the occurrence of a species of *Hepatozoon* in the *Z. longissimus*. However, *Hepatozoon* species have been reported in other genus of Colubridae including: *Hepatozoon guttata* from corn snake, *Erythranthe guttata* and *Hepatozoon sauritus* in *E. guttata* and black rat snake, *E. obsoleta*.

The prevalence of parasites were 81.8% and 15–47%, respectively (Telford *et al.*, 2002, 2004). Recently Han *et al.* (2015) described *H. chinensis* in king rat snakes (*Elaphe carinata*). The parasitemia levels of *Hepatozoon* infection was from 15–47 per 10000 erythrocytes, and 50% of specimens were infected. However the transmission of the blood parasites require to the presence of a natural vector, such as fly, tick, mite, and leech and without the presence of a vector, transmission would not be possible (Jacobson, 2007).

Serpentoplasma species (Pienaar, 1962) are small and similar in early stages of life and their anaplasmod bodies usually are less than 2.5 μm . *Serpentoplasma* along with *Sauroplasma* (Toit, 1937) are now classified in the Haemohormidiidae (Levine, 1984) (Telford, 2009). The *Serpentoplasma* reported from this study with low prevalence and low degrees of parasitaemia, only found in *N. tessellata*. The prevalence of *Serpentoplasma* in the present study is lower than that found in a recent study in *Xenagama batillifera* with 40.8 % of the infected snakes. (Ursula *et al.*, 2014). These data are showing that the degree of parasitism is dependent to ecological reserves of vectors (Jacobson, 2007). In prior study (Pienaar, 1962) reported 56 % of erythrocytes infection in some African reptiles. However scientific regards to piroplasma in reptiles on the genera *Sauroplasma* and *Serpentoplasma* are very scarce (Ursula *et al.*, 2014). According Telford (2009) the prevalence of *sauroplasma* in lizards was less than 0.1-6 % and it seems that their prevalence is generally low. In agreement of this data of our study showed less than 0.1% of specimens were infected with *serpentoplasma*. However, regarding to vacuole-like appearance of the parasites in the erythrocytes it may be sometimes overestimates. The natural vectors of *serpentoplasma* are not known, but it seems like in other piroplasmid taxa (*Babesia*, *Theileria*) ticks serve as definitive hosts (Svahn, 1974).

Rickettsiales are prokaryotic parasites of reptilian blood cells which are formed roughly spherical inclusions with diameter 3-11 μm , densely stained when they are small and bordered by a darker stain margin when they are bigger (Telford, 2009). They have been reported from Spur-thighed tortoise, *Testudo graeca* in Morocco (by Peirce and Castleman

(1974); from geckos *Hemidactylus mabouia* and *Pachydactylus bibronii* in Zambia by Patterson and Peirce (1982) and from two reptiles in Australia by Peirce and Adlard (2004). Recently Vaissi *et al.* (2016) reported that 70-100% Kaiser's mountain newt (*Neuregus kaiseri*) was infected with Rickettsiales parasites in Iran. In the present study, 16.66% of *N. natrix* and 10% of *N. tessellata* specimens were infected by *Rickettsia*. It is known that ticks and mites can transmit wide variety of the genus *Rickettsia* to reptiles (Whiley *et al.*, 2016). Desser and Barta (1984) noted that the presence of the *Rickettsia* examined in Green Frogs may be related to the feeding of potential hematophagous vectors include the leeches and the mosquitos. Nevertheless, the natural cycle of rickettsial vector in snakes of this study remains unknown.

In conclusion, our study is the first to examine the blood parasites species of snakes in Iran. Iran harbor on of most remarkable of snake in Palearctic region and no information are there on infection of the reptiles by haemogregarines. Our study indicates that informative molecular markers are needed to identification of haemogregarines alongside of morphological method.

References

- Cook CA, Netherlands EC, Smit NJ. 2016. Redescription, molecular characterization and taxonomic re-evaluation of a unique African monitor lizard haemogregarine *Karyolysus paradoxa* (Dias, 1954) n. comb. (Karyolysidae). *Parasites & Vectors* 9: 347.
- Davis JR, Boyle SA, Khana A, Gaya LJ, Grishamj M, Luque LE. 2012. Snake parasitism in an urban old-growth forest. *Urban Ecosyst* 15: 739-752.
- Desser SS, Barta JR. 1984. An intraerythrocytic virus and *Rickettsia* of frogs from Algonquin Park, Ontario. *J. Zool* 62: 1521-1524.
- Dvorakova N, Kvicerova J, Papousek I, Javanbakht H, Tiar G, Kami H, Siroky P. 2014. Haemogregarines from western Palearctic freshwater turtles (genera *Emys*, *Mauremys*) are conspecific with *Haemogregarina stepanowi* Danilewsky, 1885. *Parasitology* 141: 522-530.

- Han H, Wu Y, Dong H, Zhu S, Li L, Zhao Q, Wu D, Pei E, Wang Y, Huang B. 2015. First report of *Hepatozoon* (Apicomplexa: Adeleorina) from king ratsnakes (*Elaphe carinata*) in Shanghai, with description of a new species. *Acta Parasitol* 60(2): 266-274.
- Jacobson E. 2007. Infectious diseases and pathology of reptiles, Pimera. Boca Raton-USA.
- Javanbakht H, Široký P, Mikulíček P, Sharifi M. 2015a. Distribution and abundance of *Hemolivia mauritanica* (Apicomplexa: Haemogregarinidae) and its vector *Hyalomma aegyptium* in tortoises of Iran. *Biologia* 70(2): 229-234.
- Javanbakht H, Kvicerova J, Dvorakova N, Mikulček P, Sharifi M, Kautmand M, Marsikova M, Siroky P. 2015b. Phylogeny, Diversity, Distribution, and Host Specificity of *Haemoproteus* spp. (Apicomplexa: Haemosporida: Haemoproteidae) of Palaearctic Tortoises. *J. Eukaryot. Microbiol* 62: 670-678.
- Latifi M. 2000. The snakes of Iran. 3rd Edition. Department of Environment, Tehran, Iran.
- Levine ND. 1988. The protozoan phylum Apicomplexa, Volume 1. CRC Press Inc., Boca Raton, Florida, pp 203.
- Mebert K. 2011. The dice snake, *Natrix tessellata*: biology, distribution and conservation of a Palaearctic species. *Mertensiella* 18, DGHT, Rheinbach, Germany.
- Morrison DA. 2009. Evolution of the Apicomplexa: Where are we now? *Trends Parasitol* 25: 375-382.
- Nasiri V, Mobedi I, Dalimi A, Zare Mirakabadi A, Ghaffarifar F, Teymurzadeh S, Karimi G, Abdoli A, Paykari H. 2014. A description of parasites from Iranian snakes. *Exp Parasitol* 147: 7-15.
- Patterson JW, Peirce MA. 1982. Intraerythrocytic parasites of reptiles from Lochinvar National Park, Zambia. *Afr. J. Ecol* 20: 293-295.
- Peirce MA, Castleman ARW. 1974. An intraerythrocytic parasite of the Moroccan tortoise. *J Wildl Dis* 10: 139-142.
- Peirce MA, Adlard RD. 2004. Haemoparasites from clinical screening of reptiles in south-east Queensland, Australia. *Vet Rec* 155: 708-709.
- Pienaar UD. 1962. Haematology of some South African reptiles. Witwatersrand Univ. Pr, Johannesburg.
- Rajabi F, Javanbakht H, Sajjadi SS. 2017. A preliminary study of haemoparasites in marsh frogs, *Pelophylax ridibundus* (Ranidae) from Iran. *J Entomol Zool Stud* 5(4): 1314-1317.
- Sloboda M, Kamler M, Bulantova J, Votypka J, Modry D. 2007. A new species of *Hepatozoon* (Apicomplexa: Adeleorina) from *Python regius* (Serpentes: Pythonidae) and its experimental transmission by a mosquito vector. *J Parasitol* 93(5):1189-1198.
- Sloboda M, Kamler M, Bulantová J, Votypka J, Modrý D. 2008. Rodents as intermediate hosts of *Hepatozoon ayorgbor* (Apicomplexa: Adeleina: Hepatozoidae) from the African ball python, *Python regius*? *Folia Parasitol* 55: 13-16.
- Smith TG. 1996. The genus *Hepatozoon* (Apicomplexa: Adeleina). *J. Parasitol* 82: 565-585.
- Svahn k. 1974. Incidence of blood parasites of the genus *Karyolysus* (coccidia) in Scandinavian lizards. *Oikos (kopenhavn)* 25(1): 43-53.
- Szczerbak NN. 2003. Guide to the reptiles of the eastern Palearctic. Florida: Krieger Publishing Company. pp 260.
- Telford SR, Butler JF, Telford RS. 2002. Hepatozoonspecies (Apicomplexa: Hepatozoidae) of the corn snake, *Elaphe guttata* (Serpentes: Colubridae) and the pigmy rattlesnake, *Sistrurus miliarius barbouri* (Serpentes: Viperidae) in south Florida. *J Parasitol* 88: 778-782.
- Telford SR, Ernst JA, Clark AM, Butler JF. 2004. *Hepatozoon sauritus*: A polytopic hemogregarine of three genera and four species of snakes in North Florida, with specific identity verified from genome analysis. *J Parasitol* 90: 352-358.
- Telford SR. 2009. Hemoparasites of Reptilia, Color Atlas and Text. CRC Press, Taylor & Francis Group: Boca Raton, Florida, USA.
- Ursula H, Rüdiger K, Mutschmann F, Rinder M. 2014. Blood parasites in reptiles imported to Germany. *Parasitol Res* 113(12): 4587-99.
- Vaissi S, Parto P, Haghghi ZMS, Sharifi M. 2016. Intraerythrocytic rickettsial inclusions in endangered Kaiser's mountain

newt, *Neurergus kaiseri* (Caudata: Salamandridae). *J Appl Anim Res* 45: 1-3
Whiley H, Custance G, Graves G, Tenos J, Taylor M, Ross K, Gardner MG. 2016.

Rickettsia Detected in the Reptile Tick *Bothriocroton hydrosauri* from the Lizard *Tiliqua rugosa* in South Australia. *Pathogens* 5, 41.